



# The Incidence of Lateral Process Fracture of the Talus

Christopher P. Segler, DPM<sup>1</sup>, Mikol Anderson, DPM<sup>2</sup>, Daniel Huff, DPM<sup>2</sup>, Julia R. Crim, MD<sup>1,3</sup>.

<sup>1</sup>Podiatry Department, University of Utah Health Science Center, Salt Lake City, UT. <sup>2</sup>Department of Musculoskeletal Radiology, University of Utah Health Science Center, Salt Lake City, UT. 1. Post Graduate Year-3, 2. Post Graduate Year-2, 3. Attending Faculty and Chief of Musculoskeletal Radiology.



## BACKGROUND

The lateral process of the talus has articulations that involve both the ankle joint and the subtalar joint. Because of this, a fracture of the lateral process can affect either or both of these joints, and a fracture can result in considerable disability. The anatomic location of this structure can make visualization difficult on plain radiographs.<sup>1</sup>

Lateral process fractures were first described in 1882 when Shepherd discovered one such case during cadaveric dissection.<sup>2</sup> The first attempt at presenting a collection of clinical cases was in 1942 by Maratoli.<sup>3</sup> In the initial 25 years, only 34 cases were reported in the literature. These fractures were thought to be a rare occurrence. Although downplayed in some sense due to the infrequency of occurrence, the propensity for disability has never been understated. Hawkins presented 13 cases, of which six were missed originally.<sup>4</sup> Three of these were inadequately treated and developed significant disability.<sup>4</sup> In 1974 Murkherjee noted 13 cases in 13 months.<sup>5</sup> In his series 22% of those with residual symptoms had lateral process fractures that were missed initially and subsequently had poor functional outcomes.<sup>5</sup>

In recent years some attention has been focused on lateral process fractures with the contention that an increased incidence can be attributed to the rising popularity of snowboarding.<sup>2,5,6</sup> Yet many authors still claim these fractures to be a rarity.<sup>4,15</sup> Whether considered common or uncommon, lateral process fractures are frequently missed.<sup>2,3,4,10,12-15</sup> It has been speculated that these injuries are often missed because the clinical picture can closely mimic that of an ankle sprain.<sup>2,5,13,16</sup> The obvious difficulty in this is that poor outcomes often result when these fractures are overlooked or mistreated.<sup>3,4,10,13</sup>

Still there is considerable controversy regarding the epidemiology of these injuries. To date, no large investigation into the precise frequency of these injuries has been reported. Given the propensity for disability and poor functional outcomes with these injuries, an investigation to determine the true incidence of these fractures is warranted. The present investigation seeks to determine the rate of occurrence of lateral process fractures of the talus presenting to a major medical center.

## MATERIALS AND METHODS

A retrospective review was conducted of all ankle x-ray and advanced imaging series obtained during the 3-year interval between July 1, 2001 to June 30, 2004 at a Level I trauma center.

A brief search of these patient records was performed to determine whether or not the films were obtained as a matter of diagnostic workup for ankle injury. Only those of a subset who presented with ankle trauma were included.

Plain films of the patients meeting inclusion criteria were reviewed to determine if there was radiographic evidence of fracture of the lateral process of the talus, or any other notable fracture to the affected extremity. Review was by consensus of a PGY-2 Resident, PGY-3 Resident, and Chief of Musculoskeletal Radiology.

In cases where advanced imaging modalities such as CT or MRI were subsequently obtained as a matter of further diagnostic work-up of the affected extremity, these images were also reviewed to further delineate the extent of injury and serve as an internal control to verify the diagnostic accuracy of fracture on plain film radiography.

The total number of cases of lateral process fractures and other fractures was tallied. The frequency of each of these was calculated by dividing the sum of each group by the total number of patients presenting for ankle injury.

Mantel-Haenszel Chi-Square analysis (SAS Version 8.02, Cary, NC) was performed to determine the statistical significance of associations between lateral process fractures and other radiographic findings.

Statistical significance was defined as p<0.05.

## RESULTS

- 1,480 patients were imaged for suspected traumatic ankle injury during the 3-year study interval.
- 137 lateral talar process fractures were identified.
- The incidence of lateral process fracture was 9.3% (n=137) of patients imaged for ankle trauma.
- There were 81 (59.1%) Type I, 32 (23.4%) Type II, and 24 (17.5%) Type III lateral process fractures.
- The incidence of lower extremity fracture of any type was 52.2% (n=773).
- 59.9% (n=82) of lateral process fractures were associated with low-lying soft tissue swelling (p=0.37).
- 59.1% (n=81) of lateral process fractures were associated with other fractures (p=0.13).
- There was a significant association between posterior process and lateral process fractures (p=0.004).

	Low/Low/High soft tissue swelling	High soft tissue swelling	Associated with another fracture	Lateral ankle fracture	Medial ankle fracture	Posterior ankle fracture	Calcaneal fracture	Posterior talar process fracture	Plain fracture
All Types	59.9% (n=82) p=0.37	33.6% (n=48) p=0.27	59.1% (n=81) p=0.13	29.2% (n=40) p=0.29	18.9% (n=26) p=0.12	8.0% (n=11) p=0.38	9.5% (n=13) p=0.61	7.3% (n=10) p=0.68	5.1% (n=7) p=0.4
Type I	55.6% (n=41) p=0.37	37.8% (n=30) p=0.27	53.1% (n=40) p=0.13	32.1% (n=25) p=0.29	12.3% (n=10) p=0.12	8.6% (n=7) p=0.38	7.4% (n=6) p=0.61	2.5% (n=2) p=0.68	6.2% (n=5) p=0.4
Type II	62.5% (n=26) p=0.37	28.1% (n=11) p=0.27	68.8% (n=22) p=0.13	28.1% (n=9) p=0.29	12.5% (n=4) p=0.12	9.4% (n=3) p=0.38	12.5% (n=4) p=0.61	9.4% (n=3) p=0.68	9% (n=3) p=0.4
Type III	70.8% (n=17) p=0.37	29.2% (n=7) p=0.27	66.7% (n=6) p=0.13	28.9% (n=3) p=0.29	4.2% (n=1) p=0.12	4.2% (n=1) p=0.38	12.5% (n=5) p=0.61	20.8% (n=5) p=0.68	8.3% (n=3) p=0.4

Table 1. Radiographic findings most commonly associated with lateral process fracture

## CONCLUSIONS

- This is the largest reported series to date in both number of subjects and time-interval studied.
- This investigation found an incidence of 9.3% as compared to the frequently cited incidence of 0.86%.<sup>2</sup>
- This study shows that lateral process fractures are 10 times more common than previously thought.
- Given the propensity for disability and poor functional outcomes with these injuries, a high index of suspicion should be maintained when examining patients with traumatic ankle injury, particularly those with lateral ankle tenderness and fracture of the posterior process of the talus.

## LATERAL PROCESS FRACTURE IMAGING

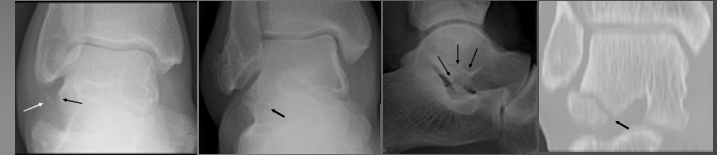


Figure 1. Type I (extra-articular) lateral process fracture visualized on the anteroposterior ankle view. Displaced fragment indicated by white arrow, denser site by black arrow.  
Figure 2. Type II (intra-articular) lateral process fracture visualized on the anteroposterior ankle view. Fracture line indicated by arrow.  
Figure 3. Type II (intra-articular) lateral process fracture visualized on the lateral ankle view. Fracture line indicated by arrow.  
Figure 4. Type II (intra-articular) lateral process fracture visualized on computed tomography. Fracture line indicated by arrow.

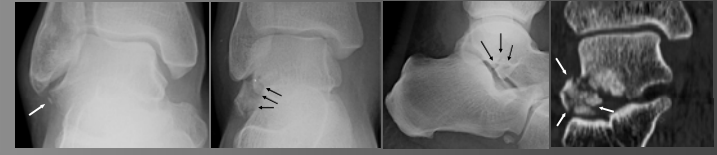

Figure 5. Type I (extra-articular) lateral process fracture visualized on the anteroposterior ankle view. Minimally displaced fragment indicated by arrow.  
Figure 6. Type III (comminuted) lateral process fracture visualized on the anteroposterior ankle view. Fracture lines indicated by arrows.  
Figure 7. Type III (comminuted) lateral process fracture visualized on the lateral ankle view. Fracture lines indicated by arrows.  
Figure 8. Type III (comminuted) lateral process fracture visualized on computed tomography. Comminuted fragment indicated by arrows.

## REFERENCES

- Borovin F, Mantel X, Copercini M, Martinioli C, Bianchi S. Imaging of fractures of the lateral process of the talus, a frequently missed diagnosis. *Eur J Radiol*. 2007 Jul;47(1):64-70.
- Funk JR, Srinivasan SC, Crandall JR. Snowboarder's talus fractures experimentally produced by eversion and dorsiflexion. *Am J Sports Med*. 2003 Nov-Dec;31(10):921-8.
- Murkherjee SK, Pringle RM, Baxter AD. Fracture of the lateral process of the talus. A report of thirteen cases. *J Bone Joint Surg Br*. 1974 May;56(2):263-73.
- Hawkins LG. Fracture of the lateral process of the talus. *J Bone Joint Surg Am*. 1962 Sep;47:1170-5.
- Copercini M, Borovin F, Mantel X, Copercini M, Martinioli C, Bianchi S. Sonographic diagnosis of talar lateral process fracture. *J Ultrasound Med*. 2003 Jun;22(6):635-40.
- Boon AJ, Smith J, Zohar MI, Amram KM. Snowboarder's talus fracture. Mechanism of injury. *Am J Sports Med*. 2001 May-Jun;29(3):333-8.
- Kirkpatrick DP, Hunter RE, Jones PC, Mastroianni J, Nicholas RA. The snowboarder's foot and ankle. *Am J Sports Med*. 1998 Mar-Apr;26(2):271-7.
- McCroly P, Bladin C. Fractures of the lateral process of the talus: a clinical review. "Snowboarder's ankle". *Clin J Sport Med*. 1996 Apr;6(2):124-8.
- Bladin C, McCroly P. Snowboarding injuries. An overview. *Sports Med*. 1995 May;19(5):355-64.
- Hickman JD, McLean MR. Fractures of the lateral process of the talus. *Clin Orthop*. 1985 Oct;(199):108-13.
- Karasick D, Schwitzer ME. The os trigonum syndrome: imaging features. *AJR*. 1996 Jun;160(1):125-9.
- Witby EH, Harrington NA. Fractures of the lateral process of the talus—the value of lateral tomography. *Br J Radiol*. 1956 Jan;58(810):583-6.
- McCroly P, Bladin C. Fractures of the lateral process of the talus: two case reports and a comprehensive literature review. *Foot Ankle Int*. 1998 Sep;19(9):641-6.
- Ebraheim NA, Meshali AD, Saljistro BJ, Mermer MJ, Jackson WT. Talar neck fractures: anatomic considerations for posterior screw application. *Foot Ankle Int*. 1996 Sep;17(9):541-7.
- Mills HJ, Home G. Fractures of the lateral process of the talus. *Aust N Z J Surg*. 1987 Sep;57(9):643-6.
- Judd DB, Kim DH. Foot fractures frequently misdiagnosed as ankle sprains. *Ann Fam Physician*. 2002 Sep;1(6):657-84.